



**PATIENT**

Lucy Duffey

**SPECIES**

Canine

**BREED**

Schnoodle

**SEX**

Female Spayed

**AGE**

10.7 years

**WEIGHT**

18.6lbs

**INTERPRETED BY**

Maggie Machen Lamy,  
DVM, DACVIM  
(Cardiology)

**IMAGING PERFORMED BY**

Amanda Crook, SDEP

**HOSPITAL NAME**

Rivers Edge Pet  
Medical Center

**REFERRING VET**

Dr. Hixson

**INVOICE**

28300

**DATE**

1/12/23

**PRESENTING CLINICAL SIGNS**

History: Grade 4/6 heart murmur, suspected Gird, lipoma on left ventrolateral thorax. Patient has a cough that seems to be exercised induced. Cough is not reported in the late night or early morning. Patient frequently burps and then seems to swallow. Consider starting Enalapril after further diagnostics. Current Medications: Pepcid 10mg ¼ T PO BID Bravecto.

**ELECTROCARDIOGRAPHIC FINDINGS**

A six lead ECG is available at 25mm/s; 10mm/mV. The average heart rate is 120bpm (range 100-150bpm). The rhythm is sinus in origin, with a p for every QRS complex and vice versa. The P wave morphology is positive with a normal dimension. Normal PR. The QRS morphology is positive with normal dimension. MEA is normal. No ectopic beats, pauses or dysrhythmias observed.

ECG diagnosis: Normal sinus rhythm with respiratory variation.

**ECHOCARDIOGRAM FINDINGS**

2D, m-mode, color flow and doppler imaging is available. Mild diffuse thickening of mitral valve leaflets with minimal prolapse into the left atrial lumen. Mild eccentric mitral regurgitation with no left atrial dilation. Normal MR velocity. Normal LV diameter with adequate myocardial function. The tricuspid valve appears normal with trace tricuspid regurgitation. Normal velocity. Normal right atrial and ventricular diameter and morphology indicating no overt evidence of pulmonary arterial hypertension. The pulmonic and aortic valves are normal in morphology and mobility. Normal pulmonic and aortic outflow velocities with laminar flow. No obvious aortic or pulmonic insufficiency. No pericardial or pleural effusion noted. No obvious cardiac masses.

**CARDIAC CHART**

CANINE CARDIAC PARAMETERS	MR VMAX (m/s)	TR VMAX (m/s)	LA/AO (Boon method)	LA/AO (Heart Base; Swe)	FS (%)	EF (%)	EPSS (cm)
NORMAL PARAMETER	4.5-5.5	<2.7	1.3	<1.6	28-40	40-100	<0.6
PATIENT	4.7	2.2	NM	1.2	49	82	NM
CANINE CARDIAC PARAMETERS	HR (BPM)	AV VMAX (m/s)	PV MAX (m/s)	BODY WEIGHT (kg)	LA 2D short axis Base view (cm)	LVIDd Avg; 2D and m-mode short axis (cm)	LVIDs Avg; 2D and m-mode short axis (cm)
NORMAL PARAMETER	50-100	0.7-1.7	0.7-1.6	BELOW	BELOW	BELOW	BELOW
PATIENT	NM	1.5	1.1	8.4	1.7	2.7	1.3
*Normal chamber parameters expressed as a mean value (SD)				3	1.27 (5.3)	2.46 (2.46)	1.36 (5.5)
<b>BODY WEIGHT DEPENDENT PARAMETERS</b>				5	1.40 (4.5)	2.74 (5.2)	1.60 (4.7)
<i>*Note: All measurements based upon multi-modal images and methods. An average value is reported.</i>				10	1.50 (3.8)	3.27 (3.5)	2.06 (3.1)
				15	1.83 (2.0)	3.71 (2.4)	2.43 (2.1)
				20	2.02 (1.9)	4.14 (2.2)	2.80 (2.0)
				25	2.18 (2.4)	4.48 (2.9)	3.10 (2.5)
				30	2.33 (3.3)	4.83 (3.9)	3.39 (3.4)
				35	2.48 (4.3)	5.17 (5.0)	3.69 (4.5)
				40	2.62 (5.2)	5.48 (6.1)	3.96 (5.4)
				50	2.88 (7.1)	6.07 (8.3)	4.46 (7.4)

Adapted from June Boon, Veterinary Echocardiography, 1998  
Rishniw M and Hollis NE, J Vet Intern Med 2000; 14:429-435  
Hansson et al, Vet Rad and Ultrasound 2002  
Bonagura et al. Echocardiography: principles of interpretation, Vet Clin North Am 15:1177, 1995



## PATIENT

Lucy Duffey

## SPECIES

Canine

## BREED

Schnoodle

## SEX

Female Spayed

## AGE

10.7 years

## WEIGHT

18.6lbs

## INTERPRETED BY

Maggie Machen Lamy,  
DVM, DACVIM  
(Cardiology)

## IMAGING PERFORMED BY

Amanda Crook, SDEP

## HOSPITAL NAME

Rivers Edge Pet  
Medical Center

## REFERRING VET

Dr. Hixson

## INVOICE

28300

## DATE

1/12/23

## INTERPRETATION OF THE FINDINGS & FURTHER RECOMMENDATIONS

Chronic degenerative valve disease causing mild mitral and trace tricuspid regurgitation. Lack of significant left atrial enlargement indicates the current risk for complication is low. No concurrent issues such as systolic dysfunction or pulmonary hypertension are noted in this study. The ECG is unremarkable with a normal sinus rhythm.

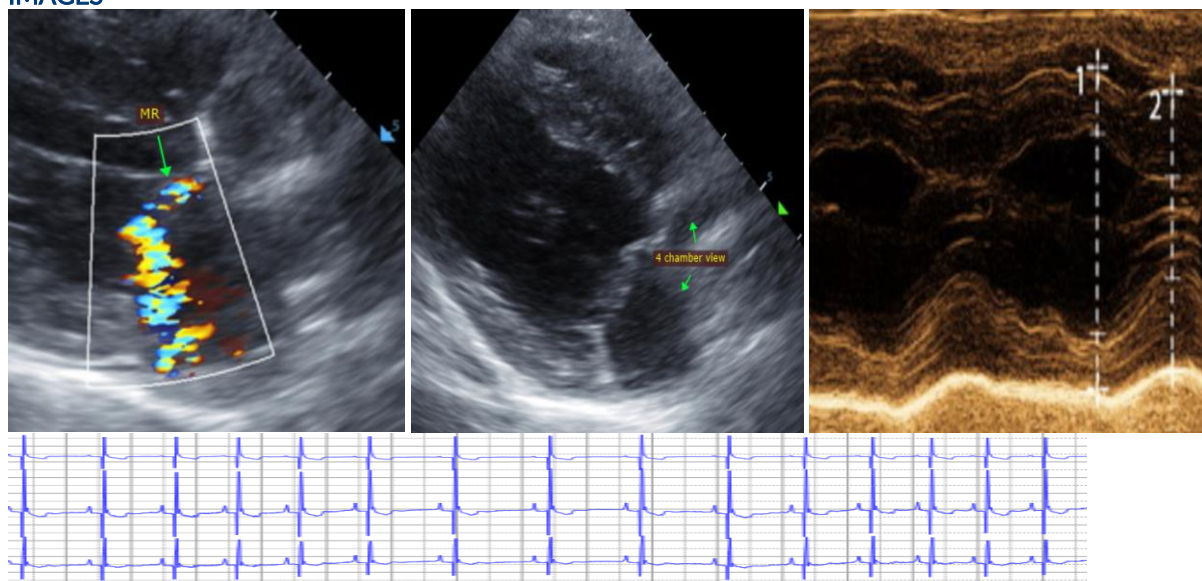
Given these findings, the cough is unlikely to be cardiac in origin and primary respiratory causes should be considered. Consider further respiratory work up/treatment (hydrocodone, taper course of steroids, Enrofloxacin, TTW/BAL, etc.).

In a dog with no significant left atrial enlargement, **no cardiac medications are clearly indicated.** Assessment of progression in the future will help predict long term prognosis, which is highly variable at this stage (B1). Omega fatty acid supplementation and mild salt restriction may be of some long-term benefit. Monitor for development of a cough, labored breathing, exercise intolerance or collapse episodes.

Anesthetic risk is considered mild if needed. Cardiac protective drug choices (opioid/benzodiazepine premedication, propofol or alfaxalone induction, isoflurane gas) are recommended. Pre-oxygenate for 5-10 minutes prior to induction. Monitor for arrhythmias, hypotension, and hypoxia both intra and post-operatively and intervene as necessary. Mild IV fluid restriction is recommended to avoid fluid overload. Avoid heart rate stimulating drugs such as atropine unless clinically indicated.

Recommend conservative monitoring with a recheck echocardiogram in 6 months, sooner if any development of clinical signs.

## IMAGES





**PATIENT**

Lucy Duffey

The information and recommendations provided are based on the images presented by the referring veterinarian. No evaluation can be communicated regarding pathology that was not visible in the image/video clips provided.

**SPECIES**

Canine

Thank you for this referral. This report was generated using transcription software, and minor dictation errors may be present. If the clinical or image interpretation does not parallel your findings or if I can be of any further assistance, please contact me.

**BREED**

Schnoodle

Maggie Machen Lamy, DVM  
Diplomate of the American College of Veterinary Internal Medicine (Cardiology)  
info@sonopath.com

**SEX**

Female Spayed

**AGE**

10.7 years

**WEIGHT**

18.6lbs

**INTERPRETED BY**

Maggie Machen Lamy,  
DVM, DACVIM  
(Cardiology)

**IMAGING  
PERFORMED BY**

Amanda Crook, SDEP

**HOSPITAL NAME**

Rivers Edge Pet  
Medical Center

**REFERRING VET**

Dr. Hixson

**INVOICE**

28300

**DATE**

1/12/23